

# Hyperostosis frontalis interna – a find in women individual from Modern Times (St. Martin Cathedral, Spisska Kapitula, Slovakia)

Eva Petrušová Chudá, Michaela Dörnhöferová

*Katedra antropologie, Fakulta přírodních věd, Univerzita Komenského v Bratislavě  
evapetrusovachuda@yahoo.com*

## Hyperostosis frontalis interna – a find in women individual from Modern Times (St. Martin Cathedral, Spisska Kapitula, Slovakia)

**Abstract**—In this study we present find of skeletal remains from the St. Martin Cathedral from the 17<sup>th</sup> – 18<sup>th</sup> centuries which were excavated in year 2008. Especially of individual from grave no. 2/2008 – preserved cranium showed marks of endocranial hyperostosis (stage B according Hershkovitz et al. 1999). Hyperostosis frontalis interna (HFI) is an overgrowth of bony tissue on the inner plate of the frontal bone of the calvaria, the irregular thickening of the endocranium (may be 1 cm or thicker). It is typically bilateral and symmetrical, and may extend to involve the parietal bones. It was first described in 1765 by Morgagni and Santorini as an obesity and virilism associated with thickening of internal table of the frontal bone called hyperostosis frontalis interna. HFI appears more commonly in women than in men, with an estimated male:female ratio 1:9, usually in age 35 years and older women. In modern population this condition is most prevalent in postmenopausal females, with frequencies of 40 – 62% reported, in general population, composed of males and females of different ages HFI affects 3 – 15% of individuals. In contrast, HFI is rarely reported in an archeological context. Using an anthropomorphological and paleopathological examination of the skeletal remains we realized that this woman was in age category adultus II (30 – 39 years) or older, her stature was cca 151.875 cm and she also suffered from DISH, healed fracture of styloid process of right ulna, osteoarthritis of humeral and femoral heads and spondylosis.

**Key Words**—hyperostosis cranii, frontal bone, woman skeletal remains, Spisska Kapitula, UNESCO, Slovakia

## INTRODUCTION

**P**ALEOPATHOLOGICAL studies are important for the assessment of both the biological condition of particular individuals and the quality of life of human populations in the past. They provide us with a vast body of information on the history and development of particular diseases in both time and space (Glab et al. 2006).

Hyperostosis frontalis interna (HFI) is characterized by sparing of the midline, bone deposition is usually limited to the inner table of the frontal bone, located

symmetrically on both sides of frontal crest, do not reach beyond the coronal suture. Histologically, there is a widened zone of the lamellar bone and there may be remodeling of the endocranial plate (Hershkovitz et al. 1999). HFI is a common phenomenon among elderly post-menopausal women and is unique and being clinical entity unrelated to other diseases of bone. The cause of HFI is unclear, but may involve hormonal influences of bone growth in the skull (She and Szakacs 2004).

Such a small number of documented historical cases are most probably a result of the fact that studies of hypertrophic HFI structures are carried out either on damaged material – on a skull whose inner profile has been exposed, or using continuous radiographic procedures.

Hershkovitz et al. (1999) and Anton (1997) discussed the differential diagnosis of HFI from other sources of cranial hypertrophy, including for example Paget's disease and leontiasis ossea. However, HFI can be differentiated from these diseases based on the morphology, distribution and the localization of lesions.

### *Paget's disease*

Paget's disease (osteitis deformans) is a chronic bone disease, which may affect a single, several, or many bones but never involves the entire skeleton (Ortner and Putschar 1981). The disease seldom appears before 40 and mostly not before 50 years of age. Males are more often involved than females. The disease process can be best characterized as a pathological speedup and distortion of the normal remodeling mechanism. It always begins as a local process but may spread through an entire bone, including the epiphyses, clear up to and involving the subchondral bone plate of the joint. In the skull the process extends readily across suture lines. The initial change is excessive osteoclastic resorption accompanied by fibrous conversion of the bone marrow and hypervascularity. This is followed by osteoblastic overstimulation, producing irregular and excessive amounts of woven and lamellar bone. Changes of fully developed Paget's disease of the cranial vault may exhibit distinct thickening of the calvarium by endocranial and external bone formation. Characteristic blastic lesions of Paget will develop either in the skull or in other areas

of the skeleton: spine, ilium, femur, tibia (Ortner and Putschar 1981).

### *Leontiasis ossea*

Leontiasis ossea is characterized by an overgrowth of the facial and cranial bones. This is a rare condition in which long-continued excessive bone formation on the cranial and facial bones leads to marked distortions of the normal features. The periosteal buildup and diploic sclerosis may be uniform or nodular. The common form is that in which one or other maxilla is affected, its size progressively increasing, and thus encroaching on the cavities of the orbit, the mouth, the nose and its accessory sinuses. In the somewhat less common form of this rare disease the overgrowth of bone affects all the cranial bones as well as those of the face (Ortner and Putschar 1981).

## ARCHEOLOGICAL BACKGROUND AND SKELETAL REMAINS

Spisska Kapitula was originally an independent village, but in 1948 it became an administrative part of the village of Spisske Podhradie. The Roman-Catholic church has had a seat there since the middle 13th century. The village was surrounded by stonewalls, built between years 1662 – 1665. In 1776 it became a seat of the Spis Holy See. In 1993 Spisska Kapitula (together with the Spis castle and surroundings Spisske Podhradie and the church in Žehra) was enlisted into UNESCO World Heritage List.

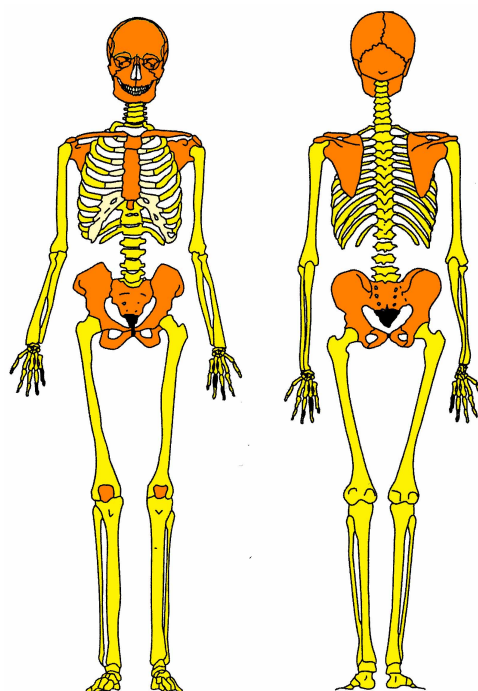
Archaeological research inside of St. Martin Cathedral in Spisska Kapitula was realized by The Monuments Board of the Slovak Republic in Bratislava because of prepared renovation of this church. During year 2008 the north nave of church was explored, in next year 2009 probing continue in north nave and new sondes were opened in north nave of antechapel and in south nave of cathedral.

During these researches few human skeletal remains were discovered, exhumated and now are anthropologically analyzed. These remains come from 17<sup>th</sup> – 18<sup>th</sup> centuries and some of them were inhumated in wooden coffins with several fittings (as wooden cross, beads, metal locket, remains of shoes and wear). All of this finds are explore (Harčar and Uličný 2010).

Skeletal remains from grave no. 2/2008 –were inhumated in anatomical position in back and belong to a woman individual, in an age category adultus II (30 – 39 years) or older. Skeleton was almost complete with only few small bones from hands and feet were missing (Fig. 1).

## METHODS

Gender was estimated according to morphological characteristics on pelvis (Brůžek 2002). Age of this individual was estimated according to degree of abrasion of permanent dentition (Lovejoy 1985), also morphological



Obrázek 1. Skeletal remains from grave no. 2/2008


changes on facies symphysialis and facies auricularis were analysed (Hanihara and Suzuki 1978; Lovejoy et al. 1985). Osteometry was realized according to methods of Martin and Saller (1957) and the stature was calculated using regression formulae by Sjøvold (1990). Morphological and epigenetic features were evaluated according to Dobisíková et al. (1999) and Hauser and De Stefano (1989). For differential diagnosis of complete skull X-ray examination with concentration on frontal bone were used because of thickening in the internal part.

## RESULTS

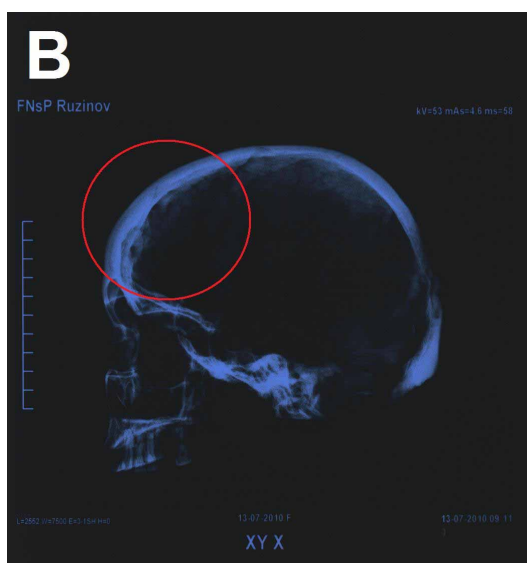
Analysed remains belong to woman individual in age category adultus II (30 – 39 years) with almost complete skeleton.

The most interesting changes found on skeletal remains were HFI as visible hypertrophic changes localized in the anterior part of the inner frontal squama (Fig. 2 and 3). The other discussed diseases such as Paget's or leontiasis ossea, no pathological changes associated with these pathologies were presented on analysed skeleton.

Columna vertebralis was suffered from spondylosis (mostly situated on cervical, also thoracic and lumbar vertebrae) (Fig. 4) and also DISH (diffuse idiopathic skeletal hyperostosis) localized on thoracic vertebrae (Fig. 5). Other diagnosed pathologies were healed fracture of styloid process of right ulna (Fig. 6), osteoarthritis of humeral and femoral heads, on articular parts of tibiae, femora and patellae. On teeth of total number 29 (because 3 were intravital missing) hypoplasia, caries, paradentosis and massive tartar were found.



Obrázek 2. Endocranial surface of the frontal bone



Obrázek 3. RTG (lateral view)

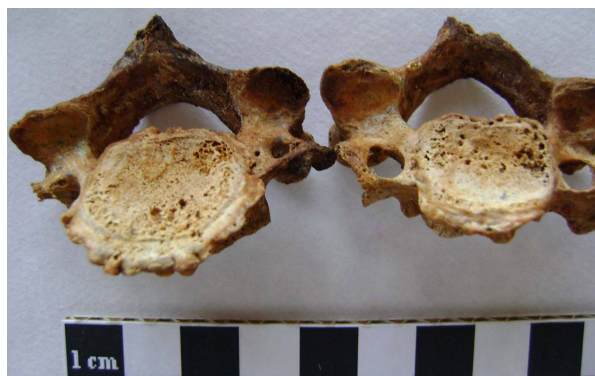Metrical analysis of skull showed normal measurements (Table 1).

Measurements	Proportions (mm)
(M5) Basion - Nasion length	90
(M8) Maximum cranial breadth	113
(M9) Minimum frontal breadth	94
(M10) Maximum frontal breadth	117
(M11) Biauricular breadth	116
(M16) Foramen magnum breath	30
(M17) Cranial heigth	127
(M40) Basion - Prosthion length	86
(M43) Upper facial	100
(M47) Total facial height	110
(M48) Upper facial height	59

Tabulka I

MEASUREMENTS AND PROPORTIONS OF ANALYSED SKULL - GRAVE 2/2008

From numerous epigenetic marks on these skeletal remains were recognized - bilateral os asterii and small individual bones in orbitae and in sutura nasalis.



Obrázek 4. Spondylosis - cervical vertebrae



Obrázek 5. DISH localized on thoracic vertebrae

## DISCUSSION

In Europe number of HFI diagnosis were found and published. In Czech Republic was diagnosed HFI as a part of Morgagni syndrome in St. Ludmila (she died in year 921 in age of 65 – 68 years), she was a grand mother of prince st. Václav (Vlček 1995, 1997). Also in Mikulčice – two women cranias with diagnosed HFI belong to a 50 – 60 years (maturus II) and 40 – 50 years (maturus I) individual (Stloukal and Vyhnánek 1976: 143). Glab et al. (2006) studied two female skeletons (who died at the age of approximately 50 and 60 years) from 16th century from Dominican Church in Raciborz (Southwest Poland) and HFI were diagnosed. Also Hajdu et al. (2009) in skeletal samples from various archeological sites in Hungary in 803 adult individuals with observable frontal bones found HFI in 15 females (3.83%) and in 5 males (1.21%). And the only Slovak published find of HFI till now was found in skull of Elizabeth Thurzo (neé Czobor, Alžbeta Thurzová), she was the wife of the Hungarian Kingdom palatine George (Juraj) Thurzo and she had health problems and HFI was also diagnosed (Thurzo et al. 2002).

Studies of historical human populations provided 57 reported HFI cases, as well as very well-documented symptoms found in a Homo erectus from the Sangiran 2 site, in a Neanderthal man from the Shanidar 5 site, and in a Neanderthal man from the Gibraltar 1 site (Anton 1997). Devriendt et al. (2004) observed HFI on the endocranial surface on the frontal bone of two elderly females from France and these observations constituted the



Obrázek 6. Healed fracture of styloid process of right ulna

first evidence for HFI in the Neolithic periods in Europe. Hershkovitz et al. (1999) showed that HFI affected 23.9% of females and 5.2% of males skulls from anatomical collections of the early 20th century but none of skulls from centuries prior to the 19th century were affected.

Mulhern et al. (2006) studied Chaco Canyon burials from New Mexico (860 – 1150 AD) of 37 adults, from them in 12 cases (32.4%) the HFI was identified, including 1 out of 12 males (8.3%) and 11 out of 25 females (44.0%), all individual but one were over age 35 years. This frequency is consistent with the frequency observed in modern populations, this may also indicate that females had a life cycle similar to that in modern populations. She and Szakacs (2004) reported a recent postmortem case of 56 years post-menopausal woman with irregular thickening of the internal surface of the frontal bone, she had also type II diabetes mellitus, morbid obesity, coronary artery disease and hypertension. Devriendt et al. (2005) on series of 1532 autopsies found 13 cases of HFI (0.8%), 12 in women and one in man, age range of affected individuals were 42 – 79 years.

Diffuse idiopathic skeletal hyperostosis (DISH) and hyperostosis frontalis interna (HFI), both found in this analysed individual are characterised by abnormal bone growth, a late age of onset, and an association with obesity, acromegaly and various metabolic disorders. Wilczak and Mulhern (2010) in their study examined the co-occurrence of DISH and HFI in a sample of 406 black and whites aged 40-102 years old from the Terry Collection (National Museum of Natural History, Smithsonian Institution). Fisher's exact tests showed the co-occurrence was significant for females. DISH was present in 19.6% of black and 29.6% of white females with HFI versus 4.76% and 2.38% of control females without HFI. A similar frequency of DISH was seen in males with HFI (20% black and 27.3% white), but this was not significantly different from the male controls without HFI (16.8% and 18.9%). The risk of developing DISH for females with HFI was nearly 8.78 times greater than for females without HFI. They

suggest that similar metabolic, genetic and environmental risk factors in the pathogenesis of the two conditions explain the observed comorbidity.

This found is only second published case from Slovakia and updates results about HFI findings, and also co-occurrence of DISH affecting female in age category 30 – 39 years and older.

## CONCLUSION

Finds of HFI in ancient skeletal remains may be underrepresented due to its location inside the cranial vault. Because in cases of remains with complete cranium no CT or RTG diagnoses are used in standard anthropological investigation. This is also the reason why this presented case is only the second find of HFI published from Slovakia.

## ACKNOWLEDGEMENT

We would like to thank to Dr. Grunt and assistants in RDG clinic in Hospital Ružinov for made radiographs. This project was supported with grant VEGA 1/0133/10 Application of geometric morphometrics to assess the exogenous traits in Early Medieval populations from Slovakia.

## POUŽITÁ LITERATURA

- [1] ANTON, S. C. 1997. Endocranial hyperostosis in Sangiran 2, Gibraltar 1 and Shanidar 5. *American Journal of Physical Anthropology*. 102: 111–122.
- [2] BRŮŽEK, J. 2002. A Method for visual determination of sex, using the human hip bone. *American Journal of Physical Anthropology*. 117(2): 157–168.
- [3] DEVRIENDT, E. et al. 2004. Two Neolithic cases of Hyperostosis frontalis interna. *International Journal of Osteoarchaeology*. 14(5): 414–418.
- [4] DEVRIENDT, E. et al. 2005. Hyperostosis frontalis interna: forensic case. *Journal of Forensic Sciences*. 50(1): 143–146.
- [5] DOBIŠÍKOVÁ, M. et al. 1999. *Antropologie. Příručka pro studium kostry*. Praha: Národní muzeum.
- [6] GLAB, H. et al. 2006. Hyperostosis frontalis interna, a genetic disease?: Two medieval cases from Southern Poland. *HOMO - Journal of Comparative Human Biology*. 57: 19–27.
- [7] HAJDU, T. et al. 2009. Appearance of hyperostosis frontalis interna in some osteoarcheological series from Hungary. *HOMO - Journal of Comparative Human Biology*. 60: 185–205.
- [8] HANIHARA, K. and T. SUZUKI. 1978. Estimation of Age from the Pubic Symphysis by Means of Multiple Regression Analysis. *American Journal of Physical Anthropology*. 48(2): 233–240.
- [9] HARČAR, P. and M. ULIČNÝ. 2010. *Archeologický výskum v interiéri Katedrály sv. Martina v Spišskej Kapitule*. Nепublikovaná správa.
- [10] HAUSER, G. and G. F. De STEFANO. 1989. *Epigenetic Variants of the Human Skull*. Stuttgart: E. Schweizerbart'sche Verlagsbuchhandlung.
- [11] HERSHKOVITZ, I. et al. 1999. Hyperostosis frontalis interna : an anthropological perspective. *American Journal of Physical Anthropology*. 109: 303–325.
- [12] IŞCAN, M. Y. and K. DERRICK. 1984. Determination of Sex from the Sacroiliac. A Visual Assessment Technique. *Florida Scientist*. 47: 94–98.
- [13] LOVEJOY, C. O. 1985. Dental Wear in the Libben Population: Its Pattern and Role in the Determination of Adult Skeletal Age at Death. *American Journal of Physical Anthropology*. 68(1): 47–56.

- [14] LOVEJOY, C. O. et al. 1985. Chronological Metamorphosis of the Auricular Surface of Ilium. A New Method for the Determination of Adult Skeletal Age at Death. *American Journal of Physical Anthropology*. 68(1): 15–28.
- [15] MARTIN, R. and K. SALLER 1957. *Lehrbuch der Anthropologie. In systematischer Darstellung mit besonderer Berücksichtigung der anthropologischen Methoden. Band 1.* Stuttgart: Gustav Fischer Verlag.
- [16] ORTNER, D. J. and W. G. J. PUTSCHAR 1981. *Identification of Pathological Conditions in Human Skeletal Remains.* Smithsonian Contributions to Anthropology. Washington: Smithsonian Institution Press.
- [17] SHE, R. and J. SZAKACS 2004. Hyperostosis Frontalis Interna: Case Report and Review of Literature. *Annals of Clinical and Laboratory Science*. 34(2): 206–208.
- [18] SJØVOLD, T. 1990. Estimation of stature from long bones utilizing the line of organic correlation. *Human Evolution*. 5(5): 431–447.
- [19] STLOUKAL, M. and L. VYHNÁNEK. 1976. *Slované z velkomoravských Mikulčic.* Praha: Academia.
- [20] THURZO, M. et al. 2002. Alžběta Thurzová (rod. Czoborová) - manželka palatína Juraja Thurzu: Antropologicko-historická a paleopatologická analýza. *Bulletin Slovenskej antropologickej Spoločnosti*. 5: 104–135.
- [21] VLČEK, E. 1995. *Osudy českých patronů.* Praha: Zvon – české katolické nakladatelství.
- [22] VLČEK, E. 1997. *Fyzické osobnosti českých panovníků, I. díl. Nejstarší Přemyslovci: Atlas kosterních pozůstatků prvních sedmi historicky známých generací Přemyslovců s podrobným komentářem a historickými poznámkami.* Praha: Vesmír.
- [23] WILCZAK, C. and D. MULHERN 2010. Co-occurrence of DISH and HFI in the Terry Collection. *International Journal of Osteoarchaeology*. (early view, Article first published online: 27. 10. 2010)